

Structural Integration Case Report: a Global Intervention Challenging the Limitations of Local Rehabilitation*

Bernice Landels, Bachelor Health Studies

Health Studies (Massage & Neuromuscular Therapy), Board Certified Structural Integrator (IASI)

Background: Conventional rehabilitation for musculoskeletal injuries post-surgery is generally site-specific and aims to return the person to 'normal' function. Commonly, conventional treatment focuses locally and little or no attention is given to comorbidities, other symptoms, postural compensations, or adaptations either pre-existing or resulting from the injury. Structural Integration (SI) is a manual therapy applied to and focusing on fascial continuities throughout the whole body. This case report explores SI as a global, whole-body intervention for rehabilitation.

Purpose: To examine the effects of a whole-body approach that addresses local and global symptoms following ankle surgery.

Methods: The Anatomy Trains Structural Integration (ATSI formerly KMI) 12-series protocol was applied and a selection of outcome measures were used to track progress and assess the efficacy of SI. Ankle mobility and function was assessed primarily using Weight-Bearing Lunge Test and Lower Extremity Functional Scale. Local pain was reported using the McGill Pain Questionnaire. General well-being was evaluated using subjective questioning and the WHO Quality of Life Questionnaire.

Results: Local results included increased mobility and function to affected leg, and reduced pain and swelling. Global results included an improvement in physical and psychological well-being, with the reduction of pain and dysfunction in other areas.

Conclusion: This case report demonstrates global benefits of a whole-body approach when structural integration is applied during rehabilitation. More clinical

research that includes SI is needed to determine if the local and global results shown in this case study can be demonstrated in additional rehabilitation populations.

KEY WORDS: anatomy trains; structural integration; fascial; rehabilitation; ankle surgery.

INTRODUCTION

Ankle injuries are a common occurrence in sport, and in field hockey account for nearly 25% of all injuries.⁽¹⁾ A trimalleolar fracture with syndesmosis dislocation,^(2,3) classified as a Weber C fracture⁽⁴⁾ (<https://radiopaedia.org/articles/weber-classification-of-ankle-fractures>), requires surgical intervention involving open reduction and internal fixation (ORIF) to stabilise the joint. Without surgery, instability, dysfunction and chronic pain may arise as future issues.⁽⁵⁾

Physiotherapy and advice leaflets^(6,7) providing injury specific protocols are provided by the National Health Service (NHS) for post-surgery rehabilitation in the United Kingdom. Secondary symptoms and pre-existing conditions or pre-disposing factors, such as posture or movement patterns, are given little consideration.

Manual therapy (MT) to aid recovery has to be sourced and paid for privately in the UK. There is a risk that these, too, will focus only on local symptoms relating to the injury/surgery.

Structural Integration (SI) is a unique 'whole-body' MT developed by Dr. Ida Rolf (1896–1979).⁽⁸⁾ With a set number of sessions (10–12) and a systematic approach,^(9,10) SI focuses on whole-body functionality rather than individual areas or symptoms. The International Association of Structural Integrators⁽¹¹⁾ (IASI) describe SI as bodywork focusing on connective tissue or fascia to "help an individual experience an optimal

* Winner, Case Report Competition, Ida P. Rolf Research Foundation, Boulder, CO, USA; <https://rolf-researchfoundation.org/>

way of moving by increasing strength, adaptability and resilience”.

Published literature on SI and rehabilitation is limited.^(12,13) Despite few clinical case studies or trials, the results recorded show positive effects on posture, gait, range of movement (ROM), balance, musculoskeletal pain, and well-being.^(14,15)

Myers,⁽¹⁶⁾ in his article 'Past as Prologue: The "Future" of SI', posited whether SI practitioners could bring value to people outside the confines of private practice, by assisting with rehabilitation during healing and recovery, and after surgery. This prospective case report explores Myer's question, and further investigates the benefits of a whole-body, global approach compared to local rehabilitation practices.

CASE PRESENTATION

Client Information

A 45-year old female paramedic injured her left (L) ankle whilst playing field hockey (Figure 1). She presented with pain and limited mobility in her L ankle, three months post-ORIF and syndesmotic reconstruction surgery (Figure 2). Pain in L hip/groin, tightness in the L knee on movement and right (R) superior neck pain with occasional "locking" as described by the client, were all secondary symptoms.

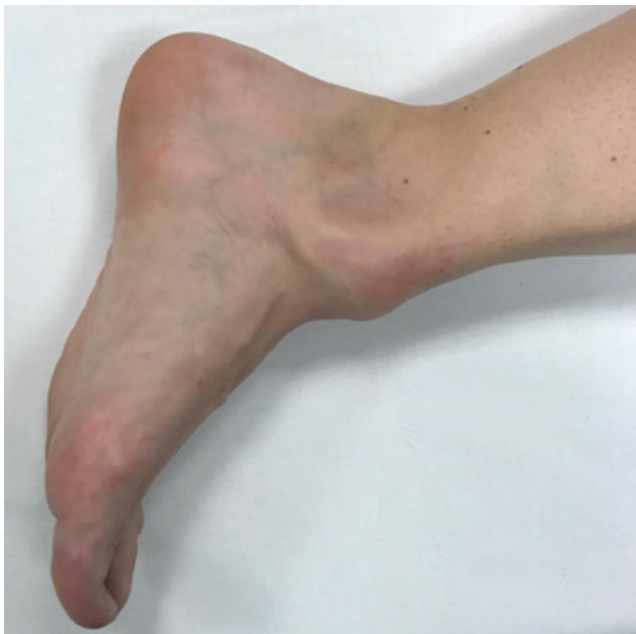

FIGURE 1. Client left ankle at time of injury.

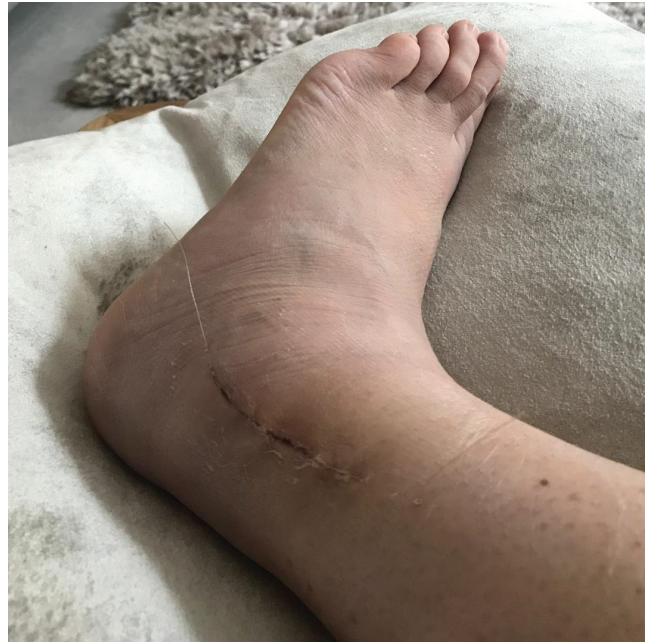

FIGURE 2. Lateral view post ORIF & syndesmotic reconstruction surgery.

Bilateral lower leg pain and discomfort had been present since 2002. Past treatment included a bilateral posterior compartment release (2008); a high volume injection (HVI) to R achilles (2015); eccentric and isometric exercises, anti-inflammatories, night splints and local massage. Initial client comments were: "I don't like my legs, ever since they started giving me grief in 2002" and "I feel flat-footed, no spring".

Surgery at eight years of age for an R inguinal hernia, a recent tooth extraction, past incidents of whiplash, and a jaw injury from playing ice hockey, as well as concussion from a fall while snowboarding, were also reported.

Assessed by NHS physiotherapists as functioning "above normal", she was discharged shortly after surgery. Seeking help to improve function and mobility, she contacted the practitioner and began a series of SI. Consent was gained for this case report.

Clinical findings from initial assessment

- Pelvis shifted and rotated R;
- R foot turned outward and pronated, driving the lower leg into internal rotation and dorsiflexion at the talocrural joint (ankle);
- R knee flexed and externally rotated, causing the femur to tilt posteriorly;

- L leg externally rotated and abducted relative to the pelvis;
- Pelvis anteriorly shifted relative to the ankles and upper body compensates by tilting thorax posteriorly;
- Head shifted anteriorly, tilted posteriorly, tilted L and rotated R;
- Shoulders neutral to pelvis with a slight L rotation;
- Bilateral scars (30 mm) midposterior calves;
- Local oedema in L ankle & muscle atrophy in lower leg; and
- Vertical scar (80 mm) on lateral L ankle from ORIF surgery.

Client walked with a limp, with no heel strike occurring on the L. Activities, such as going down stairs and putting on calf-high rubber boots, were challenging.

Assessment Measures

Baseline measurements were established comparing lower limbs, including range of movement (ROM) and function using the weight-bearing lunge test (WBLT)^(17,18) and lower extremity functional scale (LEFS).^(19,20) Photographs were taken throughout and leg circumference was a late inclusion at Session 3 to monitor local oedema. Subjective data were collected using the McGill Pain Questionnaire (SF-MPQ-2)^(21,22) and World Health Organisation Quality of Life questionnaire (WHOQOL)^(23,24) (Table 1).

Therapeutic Intervention

Anatomy Trains SI (ATSI), based on the work of Dr. Rolf, was developed by Tom Myers⁽²⁵⁾ and follows myofascial lines (or meridians) in a sequential order over 12 sessions (Table 2).^(9,10) The lines show connections throughout the body and provide a map that can help explain distribution of strain, tension, and postural compensations. A systematic review looking at the evidence behind the lines⁽²⁶⁾ found there is strong support for the Superficial Back Line (SBL) and moderate for Lateral Line (LL) and Spiral Line (SPL). A study of self-myofascial release to the plantar surface of the foot showed an increase in hamstring and lumbar ROM⁽²⁷⁾ in one foot, and stretching the calf and hamstring increased cervical ROM in another,⁽²⁸⁾ both contributing to the evidence towards the continuity of the SBL.

TABLE 1. Description of Measurement Tools Used with Supporting Rationale and Sequencing

<i>Measurement Tool</i>	<i>Rationale</i>	<i>Session</i>
Weight-bearing Lunge Test (WBLT) ^(17,18)	Measure dorsiflexion in ankle joint, track progress	1, 3, 6, 12 & F/up
Lower Extremity Functional Scale (LEFS) ^(19,20)	Measure activities of daily living relative to the lower limbs	Pre 1 Post 12
McGill Pain Questionnaire (SF-MPQ-2) ^(21,22)	To measure pain levels and types of pain relative to the L leg	Pre 1 Post 12
Quality of Life Questionnaire (WHOQOL) ^(23,24)	Measure impact of injury on everyday life and any emotional effects	Pre 1 Post 12
Leg circumference	Measure local oedema	Pre 3 Post 12

Fascial release techniques (FRT) are applied using fingers, hands, soft fists, forearms or knuckles.⁽²⁹⁾ The client is actively involved during application, moving (concentric and eccentric contraction) the area/muscle being treated. A variety of positions (seated, standing or lying) are used during the session. Depth and direction are determined by the client's tissues and assessment findings, and are applied with the intention to lift or drop, to open, differentiate or balance tissues and structures.

The ATSI 12 series took place over 12 weeks, with a follow-up session five weeks after completion. Superficial sessions (1–4) occurred regularly on Fridays and Mondays at 9:30 a.m.; core and integrating sessions (5–12) were less regular due to holidays and the client's return to work. All sessions were a maximum of 90 minutes in duration. Whilst each session has clear goals and structures to address (Table 2), variations arise based on the client's needs and presentation (Table 3).

RESULTS

Objective

WBLT improved with the difference between L and R toe-to-wall measurement reducing from 9.5 cm (34.2°) to 3 cm (10.8°) (Table 4). L lower leg oedema was reduced (Table 5 & Figure 3), and

TABLE 2. ATSI 12 Series Protocol Overview^(9,10,25)

<i>Session No.</i>	<i>Standard Protocol</i>	<i>Key Structures</i>
Superficial 1-4	Superficial front line & front arm lines (SFL/SFAL)	Ankle retinacula, crural fascia Subcostal arch, sternal fascia, sternocleidomastoid Pectoralis major, latissimus dorsi
	Superficial back line & back arm lines (SBL/SBAL)	Plantar aponeurosis, hamstring fascia Erector spinae, sub occipitals Trapezius, deltoid
	Lateral line (LL)	Fibularii fascia, iliotibial tract Lateral ribs, quadratus lumborum, scalenes
	Spiral line (SPL)	Rhombo-serratus complex, abdominal obliques Tibialis anterior/fibularis longus sling
Core 5-8	Deep front line (DFL)	Deep posterior compartment of leg Adductor group, psoas complex
	Deep front line & deep front arm line (DFAL)	Psoas, diaphragm Anterior longitudinal ligament/visceral attachments Deep laminae abdominal fascia Pectoralis minor
	Deep back line	Piriformis, deep lateral rotators, pelvic floor Calcanei, multifidi/transversospinalis
	Deep front line	Sphenoid, temporomandibular joint, hyoid complex Cervical vertebrae/deep anterior neck
Integrating 9-12	Pelvis & walking	Pelvis and legs
	Torso & breathing	Rib basket and breathing
	Arms & manipulation	SFAL - Pectoralis major/latissimus dorsi, medial intermuscular septum (IMS), flexors & carpal tunnel SBAL - Trapezius, deltoid, lateral IMS & extensor group DFAL - Pectoralis minor, biceps brachii, radial periosteum/collateral ligaments & thenar muscles DBAL - rhomboids, levator scapulae, rotator cuff, triceps brachii, ulna periosteum/collateral ligaments & hypothenar muscles
	Spine & tensegrity	Spine and integration with body

muscle tone was improved (Figure 4); re-alignment of the ankle was also observed (Figure 5). The R pelvis rotation reduced and the client’s posture (sagittal) changed with a slight posterior shift and tilt of the pelvis, softening the thoracolumbar hinge in the spine (Figure 6). Walking was closer to ‘normal’ and the client returned to hockey training (light) with her team with no adverse reactions.

Subjective

SF-MPQ-2 showed changes in the type and intensity of pain experienced

in L ankle. The intensity reducing in all types except aching pain, and two new types of pain reported at F/Up (Table 6), and overall present pain intensity (PPI) was reduced. Perceived daily functioning improved, with the LEFS score increasing from 74% to 95%. QOL responses showed improvement in overall physical and psychological well-being. The initial negative comments changed during the series to feelings of “lightness, fluid and freedom”. In Session 7 the client reported, “for one day I almost felt normal”. The client reported improvement in neck, groin, and knee symptoms.

TABLE 3. Variations to the Standard ATSI Treatment Protocol

Week	Day	Session	ATSI Focus	Variations from Standard ATSI Treatment Protocol ⁽²⁵⁾
1	Fri	1	SFL/SFAL	Lift of SFL foot to head. Arm lines not included.
2 ^a	Mon	2	SBL/SBAL	Drop of SBL, lumbar tissues worked laterally. Arm lines not included.
	Fri	3	LL	L lower lifted, upper differentiated R lower dropped from knee and lifted to head Pectoralis minor and serratus anterior not included
3 ^a	Mon	4	SPL	R upper and lower SPL. L upper SPL omitted
4 ^a	Wed/Fri	5	DFL (lower) & LL	Lift lower compartment DFL. Lift L anterior adductors, drop posterior, reverse on R. Treatment spread over 2 due to tenderness experienced in earlier sessions, this allowed for a lighter introduction to the DFL and more acceptance by the client.
5 ^a		HOLIDAY — No treatment		
6 ^b	Tues	6	DFL (upper), DFAL	Client disclosed R inguinal hernia surgery during session in response to tenderness on R. Adjusted pressure and noted scar.
	Thurs	7	Deep back line/primary & secondary curves	Lumbar/upper thoracic opened laterally, lower/mid thoracic worked toward midline
7 ^b	Fri	8	Neck, jaw and head relationship to DFL	Structures addressed for R rotation/tilt and posterior tilt of head relative to neck; jaw tracking to L.
8		HOLIDAY — No treatment		
9	Mon/Thurs	9	Integration with emphasis on gait and pelvis	Integrated with gait over 2 sessions — L forward lunge to weight bear on L, dorsiflex L ankle; external rotation of R femur/leg. R forward lunge to rotate pelvis L and extend L knee and plantar flex ankle.
10	Wed	10	Integration with emphasis on breathing and trunk	Integrated pelvic and respiratory diaphragm through focused opposing movement in standing of pelvis/ribs with breath and relative neck movement.
11	Fri	11	Arm lines and shoulder	Balancing arms and scapula relative to ribs.
12	Thurs	12	Balance of body and movement integration	Overall goal of session: Find heels, allow pelvis to tilt/shift posteriorly and lengthen lumbar. Breathe up and out rather than arch back at thoracolumbar junction (TLJ). Awareness of pelvic-respiratory diaphragm balance.

^aDenotes Occupational Physio (OP) session same week.

^bDenotes OP same day.

TABLE 4. Comparative Results for Weight Bearing Lunge Test;^(17,18) Degrees of Dorsiflexion Achieved (Toe-to-Wall Distance cm)

WBLT (cm)	R	L	Difference
Session 1	34.2° (9.5)	0° (0)	34.2° (9.5)
Follow-up	28.8° (8)	18° (5)	10.8° (3)

DISCUSSION

Overall results of this case report demonstrate SI has the potential to assist in the

TABLE 5. Comparative Results for Lower Leg Circumference Measured 20 cm from Floor

Leg Circumference (cm)	R	L	Difference
Session 3	29.6	28.8	0.8
Follow-up	28.8	28.7	(-0.1)

healing process and recovery post-surgery, addressing local and global, primary and secondary symptoms, and meeting the client’s goals.

Improvement in mobility and function were primary client goals. As pre-injury

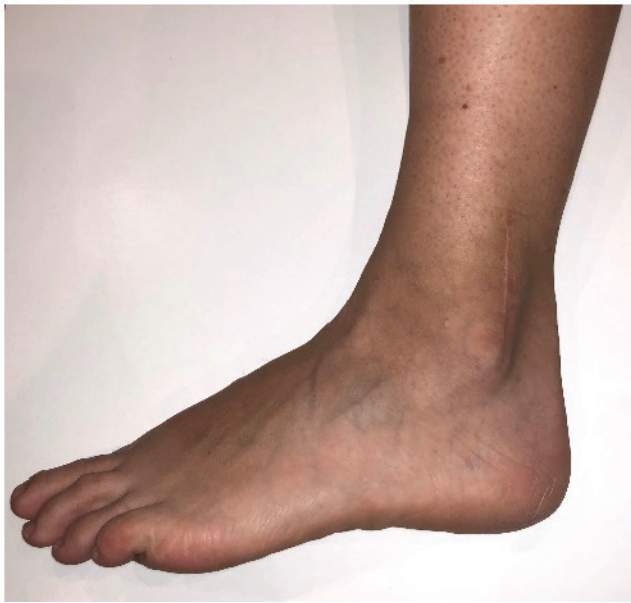

FIGURE 3. Lateral view of left ankle post treatment.

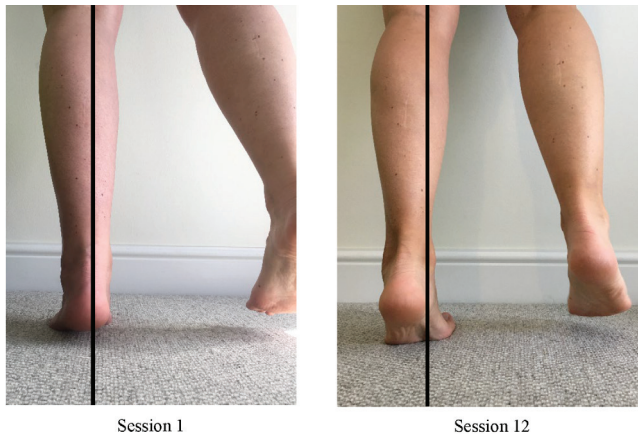

FIGURE 4. Left triceps surae activation pre- and post-treatment.

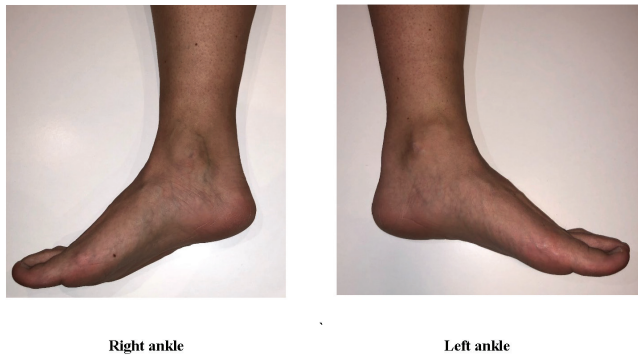


FIGURE 5. Bilateral comparison of medial ankle post-treatment.

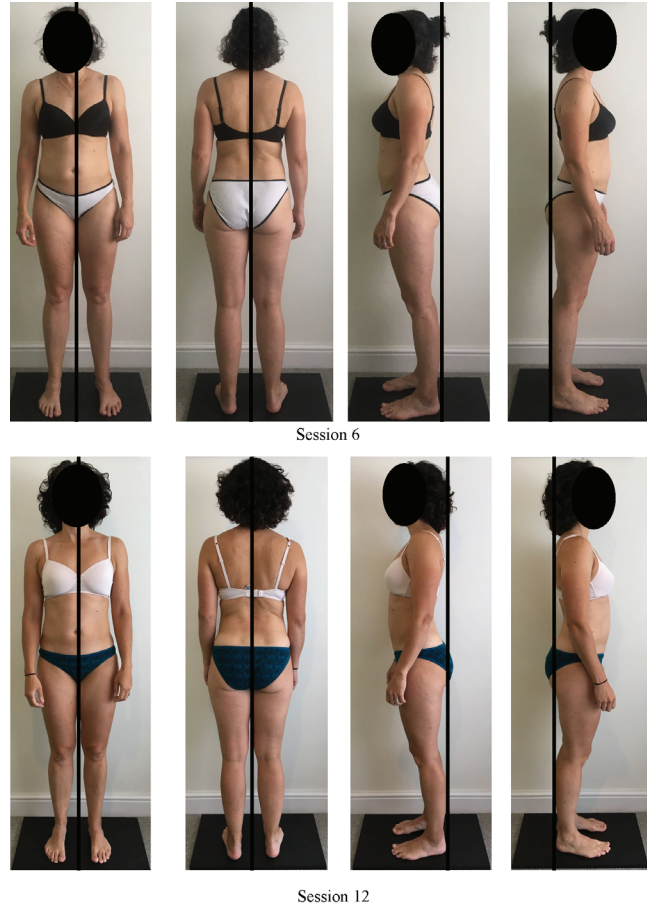
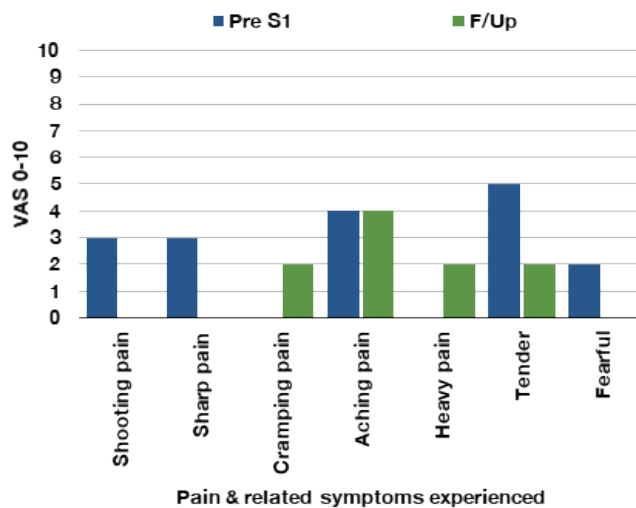


FIGURE 6. Client profile.

ROM of the L ankle was unknown, R ankle baseline measurements were established as 'normal'. The average range for non-WB ankle dorsiflexion (DF) is 20°,⁽³⁰⁾ normal walking gait requires 5–10°, while running requiring more. Toe-to-wall measurement in WBLT is calculated at 1 cm = 3.6° DF.⁽¹⁷⁾ In Sessions 1 and 3 the client recorded 0° DF on the L, a contributing factor to the limp and inability to heel strike. At follow-up the client achieved 18° DF, within the normal range for walking and closer to the range of her R ankle. Whilst there are more biomechanics involved in walking and running, DF is easily measurable and felt by the client, and restoring it is an important goal in the management of ankle injuries.⁽³¹⁾

AT lines, with the exception of the arm and functional lines, have connections in the foot and ankle.⁽²⁵⁾ Applying FRT to structures such as the ankle retinacula, plantar, and crural fascia over multiple sessions may have assisted with improving local tissue glide and improving structural relationships to enable more movement and stability.

TABLE 6. Results of SF-MPQ-2^(21,22)

Active movement by the client, in and out of gravity whilst FRT are applied, may also contribute to tissue glide. Eccentric contraction is an important mechanism of how movement is controlled and stabilization occurs in everyday life. Eccentric loading of muscles through exercise is widely used in rehabilitation.^(32,33) The client's past history of lower leg issues and objective assessments suggest that the triceps surae and lower SBL were held under tension, layers of tissue held taut and compressed together. Differentiating these tissues may have contributed to improved mobility, increased tonicity (Figure 3), and reduction in local oedema (Table 5). Working intentionally with depth and direction, actively involving the client, and the plasticity of fascia, may all contribute to the physical results.

Reduction and change in pain may also be attributed to freeing the layers of fascia around the ankle joint. The ankle retinacula are rich in nerve fibres and mechanoreceptors that contribute to proprioception. It would have been damaged by the mechanism of injury, specifically the flexor retinaculum.⁽³⁴⁾ The ankle retinacula attach into periosteum of the tibia and fibula and are inseparable from the crural fascia and the deep fascia of the foot. Further scar tissue may have occurred during surgery; as a vertical incision is made through to the bone, tissues are held apart, and metal rod is bolted to the fibula.

The client's description of L ankle pain during the series varied (Table 6). Despite reporting the PPI score as zero at follow up, the client was still experiencing localised

pain. Pain levels were only measured for the L leg and only types of pain that scored 1 or above were included in this report. There is little research on post-operative pain for ORIF and syndesmosis reduction; one study concluded that persistent post-surgical pain up to 1 year is frequent.⁽³⁵⁾ This may be true for this client since during the series, the intermittent (shooting, sharp) and affective (fearful) pains subsided. It was the persistent pains that changed in both intensity and type (cramp, ache, heavy and tender) and remained at follow-up.

The attention that SI gives to the base of support in relationship with the rest of the body by default addressed both the injured site and symptoms elsewhere in the body. 'Biotensegrity'^(36,37,38) is a model used to describe the fascial interconnected network within the body—where force is transmitted in series (longitudinally) or parallel (transversely) to neighbouring and other parts of the body. Zugel et al.⁽³⁹⁾ proposed that trauma to fascial tissues resulted in fibrotic changes effecting the entire system, thus impacting tissue dynamics and force transmission along myofascial lines and to neighbouring structures. Fracture and displacement of the tibia and fibula in relation to the talus, and surgery, will have undoubtedly affected both the compression (bones) and tensional (fascia and myofascia) components of such a model, as well as fluid dynamics. Applying the 'biotensegrity' model to AT lines helps show the myofascial connection of the foot to the hip and neck; changing tension in any part of these lines changes the relationship between structures. The gradual acceptance of more weight in the L foot, allowed for the pelvis to return to centre, taking strain off the L groin and knee. The flow-on effect up the body helps resolve the neck pain. These results and other changes observed in the client's posture (Figure 5) suggests that SI provides more whole-body benefits than those of local rehabilitation.

Changes in pain, reduced swelling, and improved ROM influenced other outcomes. The LEFS score improved significantly, with double the documented LEFS range for Minimal Detectable Change and Minimal Clinically Important Difference. This may reflect the extent of the client's restrictions prior to starting the SI series and the positive change that occurred, and there may be a correlation between the local improvements mentioned above, client awareness, and their physical and

psychological improved wellness, as reported by the WHO-QOL questionnaire.

Limitation

Several limitations of this case study have been identified. The client understood the process of SI, however, would often request more focus on the L leg, detracting from the SI protocol; and the irregularity of sessions 5–12 would affect the replicability of this study. Faster local results may be achieved by MT practitioners or physiotherapists who provide a site-specific treatment. Occupational physiotherapy (OP) provided by her employer as a ‘return to work’ programme occurred during the series between Sessions 2 and 8 (Table 3) and may have contributed to local results. Treatment included heat and local friction to scar, ankle mobilization, and strength exercises. The final two physio sessions occurred on the same days as SI Sessions 6 and 8, both of which have an upper body focus, so there was no conflict. The Hawthorne effect was considered but dismissed, as the client was highly motivated to improve at any cost, though spontaneous recovery cannot be ruled out.

Further research on SI, the benefits of a whole-body approach, and rehabilitation would be useful for SI practitioners and clients who aren’t making the improvements they’d like with conventional therapies. Results from this case report concur with those reported by Jacobson⁽¹⁴⁾ and James et al.,⁽¹⁵⁾ with improvement locally across a range of measures. There is great value in using outcome measures that are reliable and valid, and whilst limiting this to one body part is useful for research, it does not provide a full picture of the client. Using a tool that measures multiple symptoms—for example, subjective health complaints (SHC)⁽⁴⁰⁾—may provide additional rigour to this study and others alike. It would be beneficial if SI schools trained students in the use of outcome measures and case report writing, to build a culture of investigation and evidenced base practice.

The findings of this case report suggest that SI can bring added value to the process of healing and recovery, serving the client beyond the conventional realms of rehabilitation. SI is able to help meet the normal expectations of rehabilitation of increasing ROM and it does it in a relational way, systematically working through the

body to bring balance, adaptability, and resilience to the whole, not just the part.

In his article, Myers⁽¹⁶⁾ wrote, “essential-to-healing integration is what we do best”, and SI could bring finishing touches to rehabilitation, “melding the changes into the body as a whole”.

ACKNOWLEDGMENTS

Thanks to the Ida P. Rolf Research Foundation for providing the incentive to write a case report; to Sue Adstrum, PhD, for encouraging and supporting me during the case study; Abi Johnson, friend and business coach who helped start this process of investigation and having a go at writing a case report; and last, but not least, to my family.

CONFLICT OF INTEREST NOTIFICATION

The author declares there are no conflicts of interest.

COPYRIGHT

Published under the [Creative Commons Attribution-NonCommercial-NoDerivs 3.0 License](https://creativecommons.org/licenses/by-nc-nd/3.0/).

REFERENCES

1. Barboza SD, Joseph C, Nauta J, van Mechelen W, Verhagen E. Injuries in field hockey players: a systematic review. *Sports Med*. 2018;48(4):849–866.
2. Xing W, Xie P, Wang L, Liu C, Cui J, Zhang Z, et al. The application of intraoperative ankle dislocation approach in the treatment of the unstable trimalleolar fractures involving posterior ankle comminuted fracture: a retrospective cohort study. *BMC Surgery*. 2018;18(1): Article No. 23.
3. Wu Y, He Q-F, Lai L-P, Li X, Zhou J-L. Functional outcome of pronation-external rotation-Weber C ankle fractures with supracollicular medial malleolar fracture treated with or without syndesmotic screws: a retrospective comparative cohort study. *Chin Med J*. 2018;131(21):2551–2557.
4. Walker J. Assessment and management of patients with ankle injuries. *Nurs Standard*. 2014;28(50):52–59.
5. Moseley AM, Beckenkamp PR, Haas M, Herbert RD, Lin C-WC. Rehabilitation after immobilization for ankle fracture: the EXACT randomized clinical trial. *JAMA*. 2015;314(13):1376–1385.

6. Oxford University Hospitals NHS Trust. Physiotherapy Department. *Ankle Rehabilitation Stage 1: Information for Patients*. Oxford, UK: Oxford University Hospitals. Available from: <https://www.ouh.nhs.uk/patient-guide/leaflets/files/10867Pankle1.pdf>. Published July 2014. Updated July 2017.
7. Oxford University Hospitals NHS Trust. Physiotherapy Department. *Ankle Rehabilitation Stage 2: Information for Patients*. Oxford, UK: Oxford University Hospitals. Available from: <https://www.ouh.nhs.uk/patient-guide/leaflets/files/10865Pankle2.pdf>. Published Feb 2014. Updated Feb 2017.
8. Jacobson E. Structural integration: origins and development. *J Alter Comp Med*. 2011;17(9):775–780.
9. Myers TW. Structural integration: developments in Ida Rolf’s “recipe”—Part 2. *J Body Move Ther*. 2004;8(3):189–198.
10. Myers TW. Structural integration: developments in Ida Rolf’s “recipe”—Part 3: an alternative form. *J Body Move Ther*. 2004;8(4):249–264.
11. International Association for Structural Integrators. What Is Structural Integration? [IASI website page]. Seattle, WA: IASI; n.d. Available from: <https://iasi.memberclicks.net/what-is-structural-integration->
12. Lin C-WC, Donkers NA, Refshauge KM, Beckenkamp PR, Khera K, Moseley AM. Rehabilitation for ankle fractures in adults. *Cochrane Database of Syst Rev*. 2012:CD005595.
13. Jacobson EE, Meleger AL, Bonato P, Wayne PM, Langevin HM, Kaptchuk TJ, et al. Structural integration as an adjunct to outpatient rehabilitation for chronic nonspecific low back pain: a randomized pilot clinical trial. *Evidence-Based Comp Alter Med*. 2015:Article ID 813418.
14. Jacobson E. Structural integration, an alternative method of manual therapy and sensorimotor education. *J Alter Comp Med*. 2011;17(10):891–899.
15. James H, Castaneda L, Miller ME, Findley T. Rolfing structural integration treatment of cervical spine dysfunction. *J Body Move Ther*. 2009;13(3):229–238.
16. Myers TW. Past as prologue: the “future” of SI. In: *2013 Yearbook of Structural Integration*. Raleigh, NC: IASI; 2013; p. 104. Available from: <https://iasi.memberclicks.net/assets/iasi%202013%20yearbook--final.pdf>. Accessed Nov 13, 2019.
17. Konor MM, Morton S, Eckerson JM, Grindstaff TL. Reliability of three measures of ankle dorsiflexion range of motion. *Int J Sports Phys Ther*. 2012;7(3):279–287. Available from: <https://www.ncbi.nlm.nih.gov/pmc/articles/PMC3362988/>
18. Hall EA, Docherty CL. Validity of clinical outcome measures to evaluate ankle range of motion during the weight-bearing lunge test. *J Sci Med Sport*. 2017;20(7):618–621.
19. Yeung TS, Wessel J, Stratford P, MacDermid J. Reliability, validity, and responsiveness of the lower extremity functional scale for inpatients of an orthopaedic rehabilitation ward. *J Orthop Sports Phys Ther*. 2009;39(6):468–477.
20. Michigan State University Rehabilitation Clinic. The Lower Extremity Functional Scale. East Lansing, MI: Michigan State University; n.d. Available from: http://www.rehab.msu.edu/_files/_docs/LEFS.pdf
21. Lovejoy TI, Turk DC, Morasco BJ. Evaluation of the psychometric properties of the revised short-form McGill Pain Questionnaire. *J Pain*. 2012;13(12):1250–1257.
22. Physioplus. Short-form McGill Pain Questionnaire [professional members’ website]. Available from: https://www.physio-pedia.com/Short-form_McGill_Pain_Questionnaire
23. The World Health Organization. Programme on Mental Health. Quality of Life (WHOQOL) Bref: Introduction, Administration, Scoring and Generic Version of the Assessment. Geneva, Switzerland: WHO; 1996. Available from: https://www.who.int/mental_health/media/en/76.pdf
24. The World Health Organization. Programme on Mental Health. Quality of Life User Manual. Geneva, Switzerland: WHO; 1998. Available from: https://apps.who.int/iris/bitstream/handle/10665/77932/WHO_HIS_HSI_Rev.2012.03_eng.pdf
25. Myers TW. *Anatomy Trains: Myofascial Meridians for Manual and Movement Therapists*, 3rd ed. Edinburgh: Churchill Livingstone; 2014.
26. Wilke J, Krause F, Vogt L, Banzer W. What is evidence-based about myofascial chains: a systematic review. *Arch Phys Med Rehab*. 2016;97(3):454–461.
27. Grieve R, Goodwin F, Alfaki M, Bourton A-J, Jeffries C, Scott H. The immediate effect of bilateral self myofascial release on the plantar surface of the feet on hamstring and lumbar spine flexibility: a pilot randomised controlled trial. *J Body Move Ther*. 2015;19(3):544–552.
28. Wilke J, Niederer D, Vogt L, Banzer W. Remote effects of lower limb stretching: preliminary evidence for myofascial connectivity? *J Sports Sci*. 2016;34(22):2145–2148.
29. Earls J, Myers T. *Fascial Release for Structural Balance*. Berkeley, CA: North Atlantic Books; 2010.
30. Dugan SA, Bhat KP. Biomechanics and Analysis of Running Gait. *Phys Med Rehabil*. 2005;16(3):603–621.
31. Rabin A, Kozol Z, Spitzer E, Finestone AS. Weight-bearing ankle dorsiflexion range of motion—can side-to-side symmetry be assumed? *J Athletic Train*. 2015;50(1):30–35.
32. Hody S, Croisier J, Bury T, Rogister B, Leprince P. Eccentric muscle contractions: risks and benefits. *Front Physiol*. 2018;10:536.
33. Hessel AL, Lindstedt SL, Nishikawa KC. Physiological mechanisms of eccentric contraction and its applications: a role for the giant titin protein. *Front Physiol*. 2017;8:70.
34. Stecco C, Macchi V, Porzionato A, Morra A, Parenti A, Stecco A, et al. The ankle retinacula: morphological evidence of the proprioceptive role of the fascial system. *Cells Tissues Organs*. 2010;192(3):200–210.

35. Friesgaard KD, Gromov K, Knudsen LF, Brix M, Troelsen A, Nikolajsen L. Persistent pain is common 1 year after ankle and wrist fracture surgery: a register-based questionnaire study. *Br J Anaesthes*. 2016;116(5):655–661.
36. Blottner D, Huang Y, Trautmann G, Sun L. The fascia: continuum linking bone and myofascial bag for global and local body movement control on Earth and in Space. A scoping review. *J Reach*. 2019;14-15.
37. Myers TW. Tension-dependent structures in a stretch-activated system. *J Body Move Ther*. 2020;24(1):131–133.
38. Scarr G. Biotensegrity: what is the big deal? *J Body Move Ther*. 2020;24(1):134–137.
39. Zügel M, Maganaris CN, Wilke J, Jurkat-Rott K, Klingler W, Wearing SC, et al. Fascial tissue research in sports medicine: from molecules to tissue adaptation, injury and diagnostics. *Br J Sports Med*. 2018;52:1497.
40. Eriksen HR, Ihlebæk C, Ursin H. A scoring system for subjective health complaints (SHC). *Scand J of Public Health*. 1999;27(1):63–72.

Corresponding author: Bernice Landels, BA Health Studies (Massage & Neuromuscular Therapy), BCSI (IASI), 140 Church Rd., Sandford-on-Thames, Oxford OX4 4YB, UK
E-mail: bernie.landels@gmail.com